

Skull Fracture and Cranial Nerve Palsy; A Case Study

History.

An 18 year old female university student presented with multiple basal skull fractures and associated facial nerve and abducens nerve paralysis. These injuries, which were sustained during a motor vehicle accident five weeks prior to attending the clinic, resulted in visual difficulties, facial paralysis and headaches. As a consequence she was not able to attend to any academic studies. Examination at the time of the accident demonstrated multiple basal skull fractures. There was pronounced right facial palsy affecting motor function to both the upper and lower half of the right side of the face, indicative of a peripheral nerve lesion. Lateral gaze was diminished bilaterally as a consequence of bilateral abducens nerves lesions.

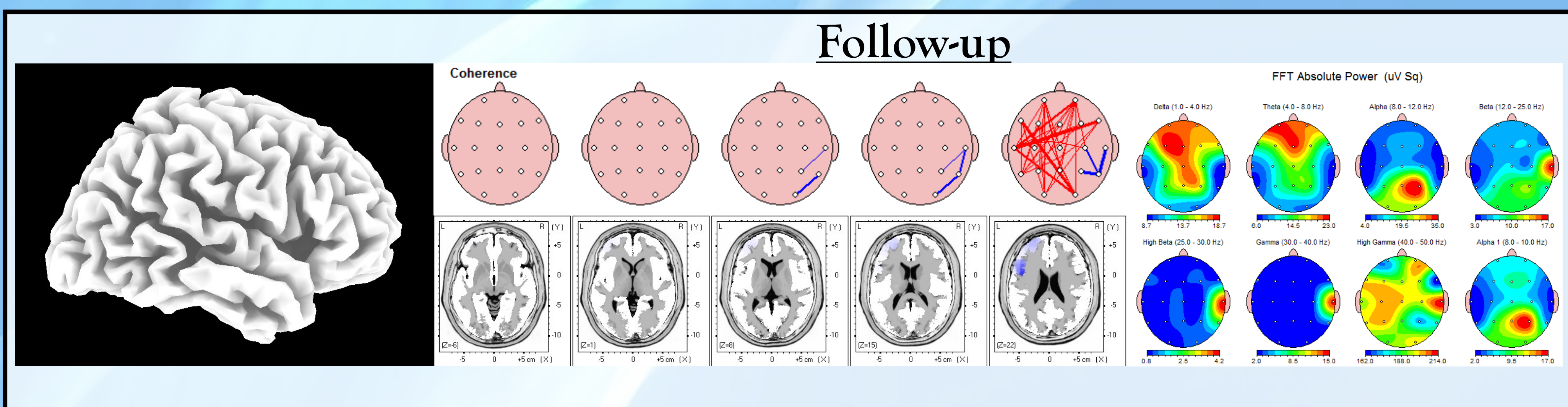
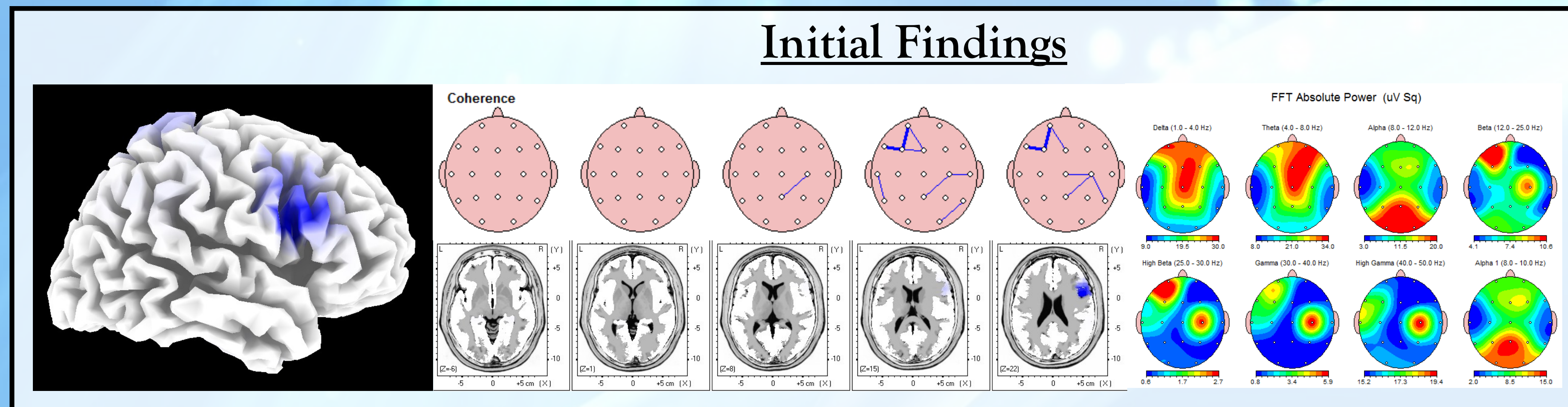
Physical Exam

At the time of the initial consultation she was not able to look to the right or the left with the ipsilateral eye. During downward gaze both eyes rotated medially and both eyes were medially deviated in the resting position. Due to the disconjugate (non-uniform) eye movements she experienced diplopia (double vision), which she compensated for by using an eye patch on one eye in order to attend to only one image therefore improving vision. She was also experiencing regular daily headaches.

In addition, the patient was unable to wrinkle her forehead on the right, there was air leak on the right when puffing out her cheeks. There was loss of the afferent component of the corneal reflex on the right and an inability to resist passive eye opening on the right.

Initial Finding

The initial quantitative electroencephalographic (QEEG) examination performed during the first consultation demonstrated a generalised right frontal hypoactive cortex, including the eye fields.



In contrast there was hyperactivity in the left frontal cortex and frontal eye fields. There was focal hyperactivity over the right facial upper motor neurons (left side of face) and a small reduction in activity in the same region contralaterally (right side of face). Treatment was therefore aimed at improving the activity in the frontal cortex and eye fields.

Follow up Findings

Follow up QEEG were performed 6 and 12 weeks after treatment commenced. After six weeks of therapy the QEEG (not shown) demonstrated a transient increase in high frequency activity in the region of the cortex supplying upper motor neurons to the right side of the face. The final QEEG (at 12 weeks) demonstrated more normal activity in left and right frontal cortices and in the cortical region representing the right side of the face. Both these findings were consistent with the overall improved vision, headaches and facial appearance experienced by the patient.

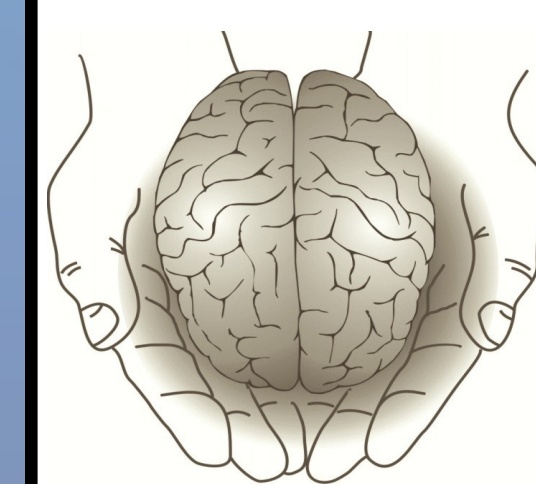
Conclusion

There was marked improvement in lateral gaze and resting eye position. She was able to focus her eyes without the aid of an eye patch and does not have double vision. Her headaches are no longer present and her face is symmetrical.

Coordinated eye movements are controlled by both the cortex and the peripheral nerves. Disruption of the cortical control mechanisms or the peripheral nerve through head injury leads to poor eye control and results in visual disturbance. Afferent cortical stimulation directed at the appropriate dysfunctional cortical areas may assist in the recovery of the visual control mechanism in a post head injury patient. QEEG may provide clinicians with a reliable tool to monitor the brain-based contributions to a patient's clinical presentation and may be useful in formulating the appropriate plan of care.

The patient reported;
"I feel like my life is getting back to normal"

She was feeling more confident in her daily activities and returned to university studies with no noticeable impairment.



Institute of Functional Neuroscience

By: Dr Jason Prior

M.Chiro, B.MedSc, B.Nursing, RN, Chiropractor