

# ADHD; A Case Study

## History.

This patient presented with symptoms of decreased concentration, poor attention and memory. At the onset of puberty he began to regress at school particularly in areas of literacy, vocalising and comprehension. His attention span worsened and he complained of low stamina levels despite being active, and had difficulty getting to sleep.

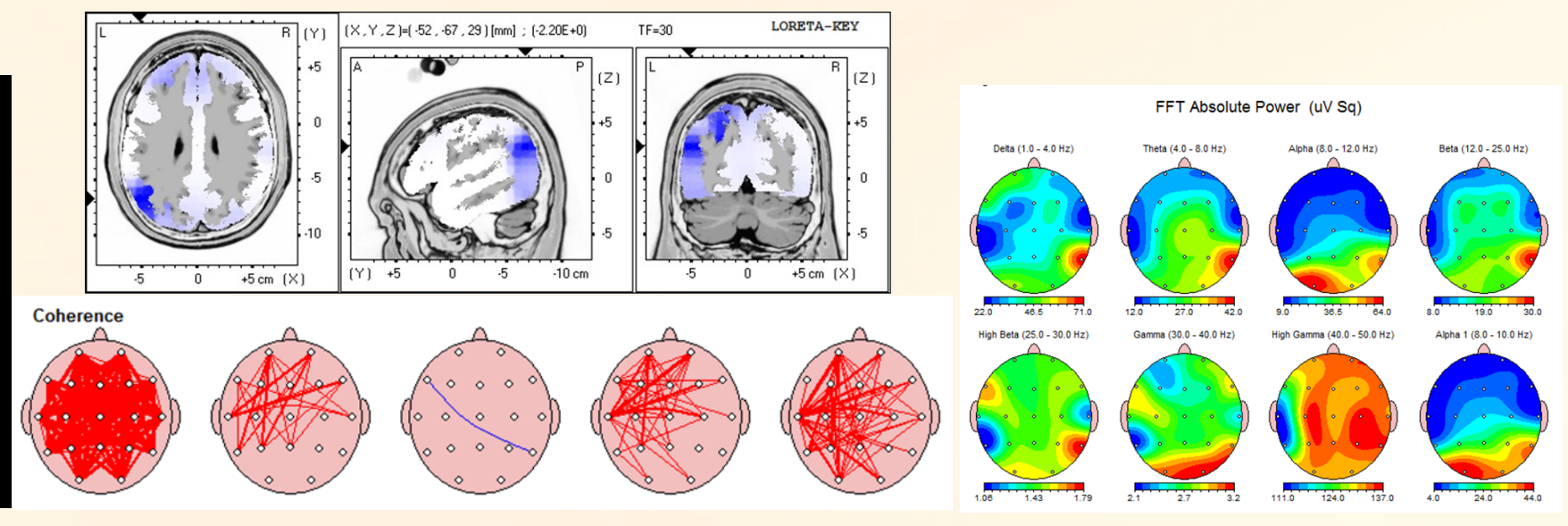
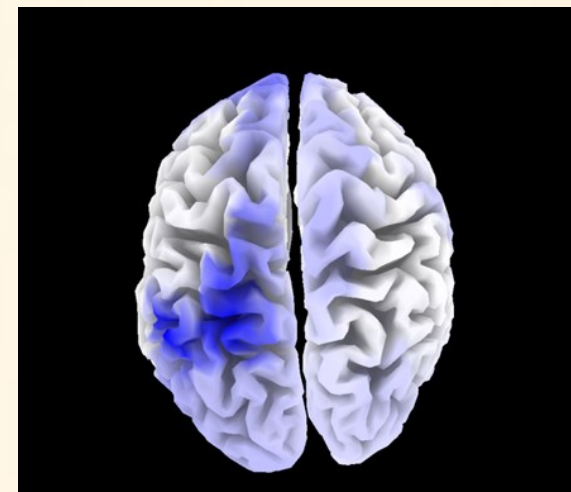## Physical Exam

On initial examination, he demonstrated a positive Romberg's and dysdiadochokinesia of the upper limb bilaterally. The pupillary light reflex and pupil size were asymmetrical. OPK testing was mildly dysmetric bilaterally. The right Achilles reflex was decreased to +1. The remainder of the cranial nerve and motor and sensory examinations were within normal limits.

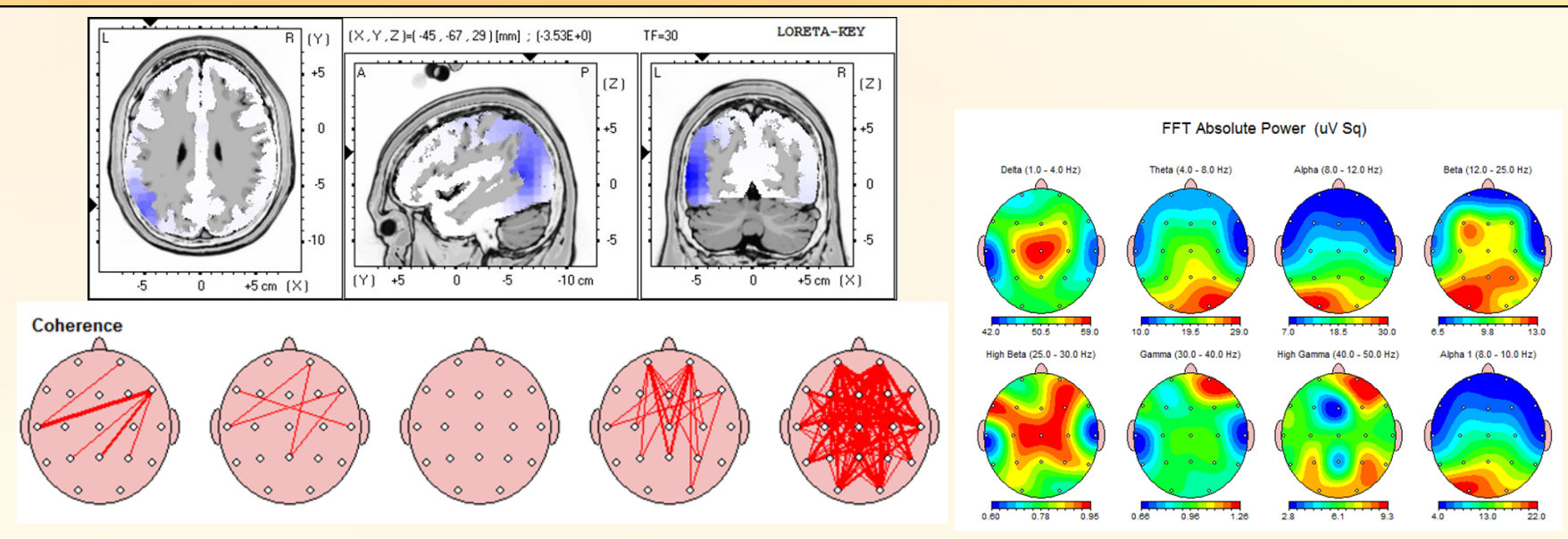
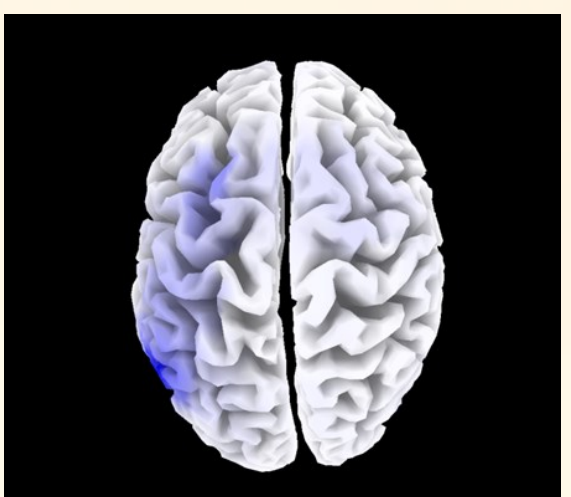
## Initial Findings:

The initial quantitative electroencephalographic (QEEG) demonstrated an area of hypoactivity in the left parietal cortex and to a lesser degree, in the right frontal-parietal cortex significant in all frequencies ranges. Hypercoherence was found throughout the cortices bilaterally in the high beta frequency. Treatment was targeted at normalising activity in the left parietal cortex. Low Resolution Electromagnetic Tomography (LORETA) analysis showed that the most significant dysfunction could be seen at Brodmann area 39 which is involved with language (sentence generation, reading), calculation, visual (spatial focusing of attention), performing verbal creative tasks and processing a sequence of actions.

## Initial Findings



## Final Findings



## Report Findings

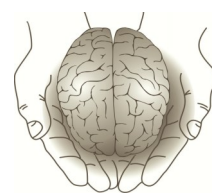
On follow-up QEEG, the left parietal cortex displayed significant normalisation of activity significant in delta, theta, alpha, beta and high beta frequencies. Residual hyperactivity is demonstrated in the occipital lobes however, this is not currently associated with any symptoms. There is significant normalization of the coherence with a residual hyperactivity in the high beta frequency. LORETA analysis shows a significant reduction in the size and extent of hypoactivity present within Brodmann area 39.

## Conclusion

After approximately 6 months of treatment, the patient's qEEG has improved significantly although not completely normalised as yet. LORETA analysis shows a decrease in size of the dysfunctional area as well as a decrease in severity or degree of dysfunction. Symptomatically, he is much more confident and is not hesitant to strike up a conversation. He is happier at school and feels like he 'belongs' more. His overall performance at school has improved drastically with increased focus, attention span and memory. He is also sleeping better and experiencing better energy levels throughout the day. He is demonstrating excellence in areas which were previously his weak points and is generally much improved.

**"Patient: I feel much more confident and comfortable within myself."**

**"Mum: He achieved an 'A' in English which was previously his weak area. He has improved with the rest of his schoolwork over all. He is a different child now!"**



**Institute of  
Functional Neuroscience**

**Dr Francesca Buhagiar** BSc., BChiro(Dist), DACNB., FAAFN